

HAL / RAR System Publications Overview



HAL & RAR System

The **safe**, **gentle** and **effective** way to treat all grades of haemorrhoids.

Zagriadskiy et al.

"Patients undergoing HAL-RAR derive greater short-term benefits, while being subject to less pain and a much lower risk of severe complications. Furthermore, they are hospitalized for a shorter length of time and may return to work earlier."

Pelviperineology 2011; **30**: 107-112

Faucheron et al.

"One of the advantages of the HAL-RAR procedure is that it can be tailored to best treat each individual case, because the number of arterial ligations depends on the blood pulsations detected, and the number of mucopexies depends on the number of prolapses identified. Particularly in this respect, the HAL-RAR technique would appear to be more suitable than many other methods."

Dis Colon Rectum 2011; **54**: 226-231

Testa et al.

"Low discomfort during the operation and the absence of complications justify the use of HAL Doppler also in patients affected by the most precocious degree of haemorrhoidal illness. With this technique both a therapeutic procedure and prophylaxis of the most advanced degree of hemorrhoidal illness may be performed at the same time."

Minerva Chir 2010; **65**: 259-65

Satzinger et al.

"The present study confirms that the RAR procedure is a very effective technique for treatment of high-grade hemorrhoids. RAR offers a variety of advantages including improved treatment of symptoms, lower pain levels, shorter hospital stays, less time off work and high patient satisfaction levels."

Pelviperineology 2009; **28**: 37-42

Wilkerson et al.

"Given the low complication rates and therefore the low risk, it may well be reasonable to offer DGHAL as a first line treatment".


"With the advent of HAL-RAR (Recto-Anal Repair), outcomes for prolapse may improve and the place of PPH may also be questioned."

Colorectal Dis 2009; **11**: 394 - 400

Bursics et al.

"In conclusion, both the closed scissors hemorrhoidectomy and the DG-HAL procedure proved effective in treating hemorrhoids in both the short and the long term."

Int J Colorectal Dis 2004; **19**: 176-80

No.	Author Procedure Date	Title	Number of patients	Grade				Follow-up
				I	II	III	IV	
1	 Zagriadskiy et al. HAL-RAR vs. CH Published 2011	Transanal Doppler-guided Hemorrhoidal Artery Ligation and Recto Anal Repair vs Closed Hemorrhoidectomy for treatment of grade III-IV hemorrhoids. A randomized trial	135			Grades III - IV*		15 months (mean)
2	 Faucheron et al. HAL-RAR Published 2011	Doppler-Guided Hemorrhoidal Artery Ligation and Rectoanal Repair (HAL-RAR) for the Treatment of Grade IV Hemorrhoids: Long-Term Results in 100 Consecutive Patients	100				100%	34 months (mean)
3	 Forrest et al. HAL-RAR Published 2010	Doppler-guided haemorrhoidal artery ligation with recto anal repair: a new technique for the treatment of symptomatic haemorrhoids	77			16%	84%	13 months (mean)
4	 Testa et al. HAL Published 2010	Doppler-guided hemorrhoidal artery ligation (DG-HAL): a safe treatment of II-III degree hemorrhoids for all patients. Could it be potentially also good prophylaxis?	128		22%	72%	6%	36.5 months (mean)
5	 Theodoropoulos et al. HAL-RAR Published 2010	Doppler-Guided Haemorrhoidal Artery Ligation (DGHAL), Rectoanal Repair (RAR), Sutured Haemorrhoidopexy (SHP) and Minimal Mucocutaneous Excision (MMCE) for Grade III-IV Haemorrhoids: A Multicenter Prospective Study of Safety and Efficacy	147			65%	35%	15 months
6	 Satzinger et al. HAL-RAR Published 2009	Recto Anal Repair (RAR): a viable new treatment option for high-grade hemorrhoids. One year results of a prospective study.	83			90%	10%	12 months
7	 Wilkerson et al. HAL Published 2009	Doppler-guided haemorrhoidal artery ligation: long-term outcome and patient satisfaction	113	Grades I - III**				30 months
8	 Walega et al. HAL Published 2008	Two-center experience in the treatment of hemorrhoidal disease using Doppler-guided hemorrhoidal artery ligation: functional results after 1-year follow-up	507		28%	63%	9%	12 months
9	 Faucheron et al. HAL Published 2008	Doppler-Guided Hemorrhoidal Artery Ligation for the Treatment of Symptomatic Hemorrhoids: Early and Three-Year Follow-up Results in 100 Consecutive Patients	100		1%	78%	21%	3 years
10	 Dorn et al. HAL Published 2007	5 Years of HAL: Experience and Long-Term Results. A Prospective Study	200	42%	38%	20%		5 years
11	 Scheyer et al. HAL Published 2006	Doppler-guided hemorrhoidal artery ligation	308		29%	62%	9%	18 months
12	 Bursics et al. HAL Published 2004	Comparison of early and 1-year follow-up results of conventional hemorrhoidectomy and hemorrhoid artery ligation: a randomized study	60	1%	22%	32%	45%	12 months

* No differentiation made between grades for the purposes of the study

Abstract: Zagriadskiy et al.*Pelviperineology 2011; 30: 107-112*

Objective: HAL-RAR is a technique whereby Doppler-guided ligation of hemorrhoidal arteries is combined with a mucopexy of the mucosal prolapse, known as Recto Anal Repair (RAR). HAL-RAR is presented here as an alternative to hemorrhoidectomy. Early and 1-year follow-up results of the procedure are presented and compared with those of closed-scissors hemorrhoidectomy (CH) in a prospective randomized study.

Patients and methods: One hundred and thirty-five patients with grade III-IV hemorrhoids were randomized for HAL-RAR (n = 65) or CH (n = 70). All operations were done under general anesthesia and local block as day-case surgery.

Results: Comparing the two groups, there was no significant difference between them in terms of the operating time (36.2±2.3 vs. 35.5±3.1 p>0.05), or when the first post-operative bowel movement occurred. The median pain score was higher for the CH group during the first ten days (p<0.05). The average need for minor analgesics was 32.3±12.6 mg (ketorolac trometamin) in the HAL-RAR group, and 46.1±7.7 mg in the CH group (p<0.001). Patients in the HAL-RAR group spent 18.3±3.5 hours in the hospital postoperatively, and those in the CH-group 62.0±12.4 hours. Patients in the HAL-RAR group returned to normal daily activities after 2.8±0.7 days, and those in the CH group after 21.1±2.7 days (p<0.001). Complications occurred in a total of five patients within 30 days of surgery: three patients from the CH group suffered from urinary retention, one patient from the CH group from bleeding, and one from the HAL-RAR group from a thrombosed hemorrhoid. The appearance of skin tags (HAL-RAR 9 vs. CH 1, p=0.047) significantly differed between the groups. Neither the re-appearance of prolapse (3 HAL-RAR vs. 0 CH patients) nor the recurrence of the symptoms bleeding (HAL-RAR 2 vs. 1 CH patients) or pain (HAL-RAR 0 vs. 1 CH patients) differed significantly between the two groups.

Conclusion: HAL-RAR appears to cause less postoperative pain and results in better patient satisfaction in the early postoperative period than closed hemorrhoidectomy. Doppler-guided hemorrhoidal artery ligation fulfills the requirements of minimally invasive surgery and appears to be ideal for 1-day surgery.

Abstract: Faucheron et al.*DIS Colon Rectum 2011; 54: 226-231*

Objective: The purpose of this study was to describe our experience with this combined procedure [Doppler-guided hemorrhoidal artery ligation (DGHAL) with transanal rectoanal repair (mucopexy)] in the treatment of grade IV hemorrhoids.

Design: Prospective observational study.

Setting: Outpatient colorectal surgery unit.

Intervention: Hemorrhoidal artery ligation-rectoanal repair.

Patients: Consecutive patients with grade IV hemorrhoids treated from April 2006 to December 2008.

Results: A total of 100 consecutive patients (64 women, 36 men) with grade IV hemorrhoids were included. Preoperative symptoms were bleeding in 80 and pain in 71 patients; 19 patients had undergone previous surgical treatment for the disease. The mean operative time was 35 (range, 17 - 60) minutes, with a mean of 9 (range, 4 - 14) ligations placed per patient. Eighty-four patients were discharged on the day of the operation. Nine patients developed early postoperative complications: pain in 6, bleeding in 4, dyschezia in 1, and thrombosis of residual hemorrhoids in 3. Late complications occurred in 4 patients and were managed conservatively. Recurrence was observed in 9 patients (9%), with a mean follow-up of 34 (range, 14 - 42 months).

Limitations: The 2 main weaknesses of the study were the lack of very long-term follow-up and the absence of a comparison with hemorrhoidectomy or hemorrhoidopexy.

Conclusion: Doppler-guided hemorrhoidal artery ligation with rectoanal repair is safe, easy to perform, and should be considered as an effective option for the treatment of grade IV hemorrhoids.

Abstract: Forrest et al.*Int J Colorectal Dis; Online: 22 April 2010*

Purpose: Doppler-guided haemorrhoidal artery ligation (DGHAL) is a minimally invasive surgical technique used to treat symptomatic haemorrhoids. In 2005, the DGHAL proctoscope was redesigned to incorporate a window through which a recto anal repair (RAR) could be performed to improve the outcome in patients with significant prolapse symptoms. The aim of this study was to observe the outcome of a series of consecutive DGHAL-RAR procedures.

Method: Seventy-seven consecutive patients (49 male) underwent DGHAL-RAR for symptomatic haemorrhoids and were reviewed for a minimum of 6 months post-surgery.

Results: Fifty-seven (74%) of patients presented with both prolapse and bleeding symptoms. The median number of DGHALs performed was six, and the median number of RARs was two. Most (96%) patients were discharged the same day. At follow-up, 11 patients complained of recurrent symptoms (five of prolapse, four of bleeding and two of pruritus). Eight patients suffered with post-operative anal fissures. The procedure is recommended by 84.4% of patients 6 weeks post-surgery.

Conclusion: DGHAL-RAR is safe, effective and well tolerated. It reduces the need for potentially dangerous excisional procedures. The RAR component is an effective addition to DGHAL in the short term for the treatment of prolapse, but longer follow-up will be required to demonstrate durability of the technique.

Abstract: Testa et al.*Minerva Chir 2010; 65: 259-65*

Aim: Doppler-guided hemorrhoidal artery ligation (HAL Doppler) is an innovative hemorrhoid treatment mainly utilised for II-III degree where bleeding is a predominant symptom. This procedure aims at dearterialization of the internal hemorrhoidal plexus by ligation of the terminal branches of the superior rectal artery detected using a special proctoscope and ultrasound system; the procedure is performed entirely above the dentate line, so it is genuinely painless. The aim of this study was to evaluate the efficacy, safety and invasivity of HAL Doppler technique to treat II and III degree hemorrhoids.

Methods: The authors treated 148 patients, from May 2002 to December 2007, principally affected by II-III degree hemorrhoids characterized by bleeding and pain at evacuation. These patients were examined in a retrospective observational study of 128 patients, 86% of the group. Follow-up varied from 5 up to 72 months with an average observation time of 36.5 months.

Results: Success was registered in 90% of patients affected by II-III degree hemorrhoids and the absence of major complications (hemorrhage, incontinence, stenosis, perforation, sepsis).

Conclusion: The authors suggest the safety, efficacy and low invasivity of HAL Doppler for treatment of II-III degree hemorrhoids, which also found in the literature, and highlight its use in treating patients with unhealthy conditions which are a contraindication to the usual surgical treatments. Moreover, they suppose the use of HAL Doppler in low degree hemorrhoids as a therapeutic and also prophylactic rule of advanced degree.

Abstract: Theodoropoulos et al.*Colorectal Dis 2010; 12: 125-134*

Objective: The isolated use of Doppler-guided haemorrhoidal artery ligation (DGHAL) may fail for advanced haemorrhoids (HR; grades III and IV). Suture haemorrhoidopexy (SHP) and mucopexy by rectoanal repair (RAR) result in haemorrhoidal lifting and fixation. A prospective evaluation was performed to evaluate the results of DGHAL combined with adjunctive procedures.

Method: The study included 147 patients with HR (male patients: 102; grade III: 95, grade IV: 52) presenting with bleeding (73%) and prolapse (62%).

Results: More ligations were required for grade IV than grade III HR (10.7±2.8 vs 8.6±2.2, P<0.001). SHP (28 patients) and RAR (18 patients) at 1-4 positions were deemed necessary in 46 (31%) patients. Minimal (muco-)cutaneous excision (MMCE) was added in 23 patients. SHP/RAR was applied more frequently in grade IV HR (60%vs16%, P<0.001). In patients not having MMCE, SHP/RAR was added in 57% of grade IV cases (P<0.001). Complications included residual prolapse (10; two second surgery), bleeding (15; two second DGHAL), thrombosis (four), fissure (three) and fistula (one). Analgesia was required not at all, up to 1-3 days, 4-7 days and >7 days by 30%, 31%, 16% and 14% of the patients, respectively. SHP/RAR was associated with greater discomfort (17%vs6%, P<0.001). No differences were found between SHP and RAR. At an average follow-up of 15 months, 96% of patients were asymptomatic and 95% were satisfied.

Conclusions: DGHAL with the selective application of SHP/RAR is a safe and effective technique for advanced grade HR.

Abstract: Bursics et al.*Int J Colorectal Dis 2004; 19: 176-80*

Background and aims: Doppler-guided hemorrhoid artery ligation is a new approach for treating hemorrhoids. Early and 1-year follow-up results of the procedure are presented and compared with those of closed scissors hemorrhoidectomy in a prospective randomized study.

Patients and methods: Sixty consecutively recruited patients were randomized into two groups: group A (n=30) was treated with standardized closed scissors hemorrhoidectomy and group B (n=30) with Dopplerguided hemorrhoid artery ligation. The follow-up period was 11.7±4.6 months.

Results: The average need for minor analgesics was 11.7±12.6 doses in group A and 2.9±7.7 in group B. Patients in group A spent 62.9±29.0 hours in hospital postoperatively and those in group B 19.8±41.8 hours. Return to normal daily activities took 24.9±24.5 days in group A and 3.0±5.5 days in group B. Neither the disappearance (26 vs. 25 patients) nor the recurrence of preoperative symptoms (5 vs. 6 patients) differed significantly between the two groups.

Conclusion: Both procedures were effective in treating hemorrhoids. The 1-year results of Doppler-guided hemorrhoid artery ligation do not differ from those of closed scissors hemorrhoidectomy. Doppler-guided hemorrhoid artery ligation seems to be ideal for 1-day surgery, and it fulfills the requirements of minimally invasive surgery.

NHS National Institute for Health and Clinical Excellence (UK)

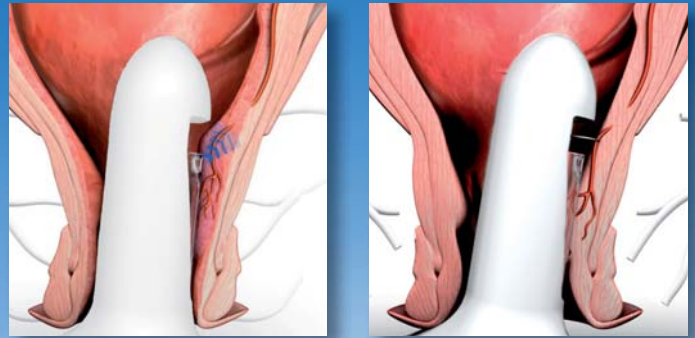
Guidance: "Current evidence on haemorrhoidal artery ligation shows that this procedure is an efficacious alternative to conventional haemorrhoidectomy or stapled haemorrhoidopexy in the short and medium term, and that there are no major safety concerns. Therefore this procedure may be used provided that normal arrangements are in place for clinical governance, consent and audit."

NICE interventional procedure guidance 342; Issue date: May 2010 <http://guidance.nice.org.uk/IPG342>

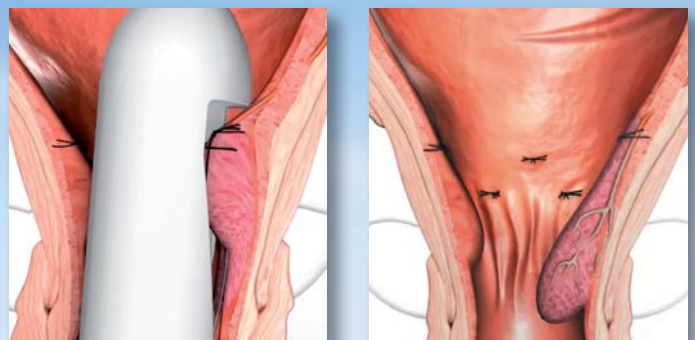
The HAL-RAR system is a complete solution for treatment of haemorrhoids, comprising an electronic unit with special probes designed for both artery ligation and mucopexy of prolapsing mucosa in one sitting.

HAL (Haemorrhoidal Artery Ligation) involves the use of Doppler ultrasound technology to allow the precise detection of haemorrhoidal arteries in each individual patient. This method is extremely effective in addressing the symptoms of haemorrhoidal disease, and can be used alone to treat low or medium grade haemorrhoids, or in conjunction with the mucopexy for higher grades. The ligations serve to reduce the arterial blood supply, causing the haemorrhoidal cushions to shrink back to normal size. As a rule, between five and seven arteries will be found during the procedure, however this number can vary from patient to patient and may also depend on the severity of the haemorrhoids in each case.

The **RAR (Recto Anal Repair)** method is used to treat the prolapsing haemorrhoids that occur during more advanced stages of the disease. Once the arteries have been ligated, one or more mucopexies can be made in various positions using the same probe. After an initial stitch has been made as far proximal as possible, the special ligation window is slowly opened by turning the handle, gradually releasing more and more prolapsing mucosa. This is gathered up by a running suture from proximal to distal, which ends just above the dentate line. This suture is then knotted to the initial stitch, lifting the prolapsing tissue back up into position.



HAL - Doppler-guided detection of arteries and subsequent ligation



RAR - Placement of running stitch above the dentate line from proximal to distal, and subsequent lifting of prolapsing tissue back up towards the initial stitch

Advantages of HAL and RAR

Since the introduction of these minimally-invasive methods, many tens of thousands of patients have been treated with them and excellent results achieved in terms of effectiveness, patient-friendliness and safety.

Effective

- Treatment of the three main symptoms - bleeding, itching and pain - with HAL
- Treatment of the prolapse with RAR

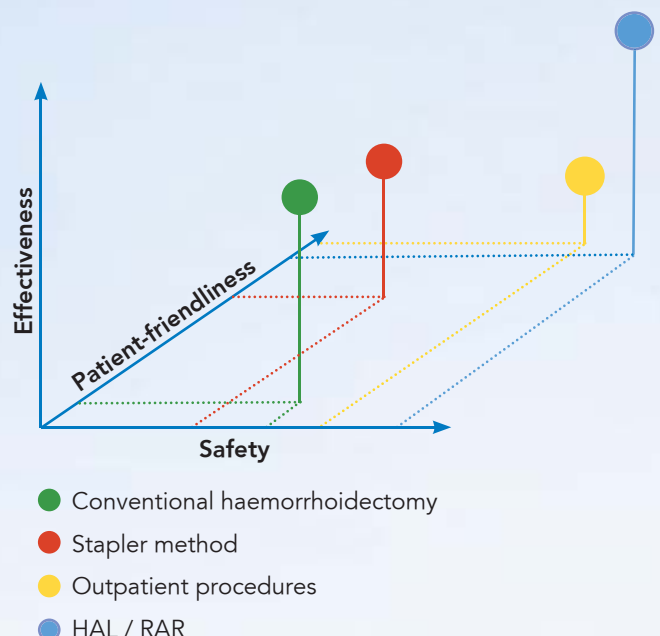
Patient-friendly

- Minimal pain
- Quick recovery

Safety

- Fewer intra-operative complications
- Fewer post-operative complications

The operation can be tailored to suit each individual patient!



This diagram represents an assessment made by A.M.I. based partly on published data and partly on evaluations by surgeons experienced with the HAL & RAR methods.

A.M.I. Agency for Medical Innovations GmbH

Im Letten 1

6800 Feldkirch . Austria

t +43 5522 90505-0

f +43 5522 90505-4006

e info@ami.at . www.ami.at

A.M.I.[®]
Agency for Medical Innovations